Long-term cannulation of the ovarian vein in mares

Robert L. Linford, DVM, PhD; Patrick M. McCue, DVM; Stephane Montavon, DVM; Bill L. Lasley, PhD

SUMMARY

A cannulation technique was developed to collect blood samples from the ovarian vein of mares over an extended period. Ovarian venous cannulae placed in 4 mares remained patent for a mean (± SEM) duration of 36.8 (± 6.2) days. During mid-diestrus, concentrations of progesterone in the ovarian vein ipsilateral to the corpus luteum (1,663.8 ± 238.8 ng/ml) were significantly ($P < 0.001$) higher than concentrations measured in paired samples from the jugular vein (6.1 ± 0.3 ng/ml). Concentration of estradiol in the ovarian vein ranged from a mean of 1,053.2 ± 303.1 pg/ml during diestrus to 3,353.8 ± 1,052.8 pg/ml during estrus, whereas values for 74% of samples collected concurrently from the jugular vein were near or below the sensitivity of the assay (10 pg/ml).

Results of the study indicate that patent long-term ovarian vein cannulation can be achieved in mares. The cannulation technique provides access to important fundamental information on equine reproductive endocrinology, which to our knowledge, has not been available.

Hormonal events associated with follicular development, ovulation, and pregnancy in mares have been traditionally studied by measuring concentrations of ovarian steroids in venous blood.[1,2] However, this approach does not allow for differentiation of hormone production from each of the ovaries or from the ovaries vs the fetal-placental unit during pregnancy. In addition, measurement of hormones in the circulation may not accurately reflect ovarian production, because dilution of the ovarian effluent by the vascular space and hepatic metabolism and conjugation may dampen the secretory dynamics, as well as recognition of steroid hormones. Collection of blood samples directly from the ovarian vein has been used to overcome these problems and to better characterize ovarian secretory dynamics in several domestic animal species.[3-7] Most studies involve collection of single samples of ovarian vein effluent because maintenance of patent ovarian vein cannulae has proven to be difficult over an extended period.[8] Successful long-term ovarian vein cannulation in mares would allow the characterization of important aspects of reproductive endocrinology that have as yet been incompletely documented.

Therefore, the primary objective of the study reported here was to develop a cannulation technique to collect ovarian venous blood from mares that would allow serial sample collection for an extended period. A secondary objective was to define the concentration gradient of ovarian steroid hormones between the ovarian and jugular veins.

Materials and Methods

Mares and ovarian vein cannulation—Seven adult mares undergoing normal estrous cycles and ranging in age from 6 to 12 years were studied. A cannula was placed into the ovarian vein ipsilateral to the dominant follicle in each of 4 mares on day 2 or 3 of estrus. A single ovarian venous blood sample was collected from 3 additional mares by use of similar surgical approach to confirm hormone concentrations in ovarian vein plasma obtained via the cannulation technique.

Surgical technique—The surgical approaches for ovarian vein cannulation and single ovarian venous blood sample collection were similar. After sedation (acepromazine maleate,[a] 0.044 mg/kg of body weight, IV; xylazine,[b] 0.44 mg/kg, IV; butorphanol tartrate,[c] 0.011 mg/kg, IV), aseptic preparation, and regional anesthesia, standing flank laparotomy, using a modified grid incision, was used to expose 1 ovary, the uterine horn, and the utero-ovarian vasculature. The ovary, broad ligament, and uterine horn tip were then wrapped with a 10 × 15-cm cloth laparotomy sponge that had been soaked in 2% lidocaine.[d] Visualization and manipulations were faciliated by use of a large self-retaining abdominal retractor to spread the abdominal musculature at the wound margins. The ovarian vein was identified, and the peritoneum comprising the dorsal surface of the broad ligament was gently incised and dissected from the vasculature near the ovary and for a distance of 8 to 10 cm proximally. A tributary of the ovarian vein was then isolated near the ovary and cannulated with either 7.3-F medical-grade silastic tubing[e] (n = 1) or medical-grade polyvinyl chloride (PVC) tubing[f] (1.3-mm ID × 2.3-mm OD; n = 3).

The tip of the cannula was advanced to a point immediately proximal to the confluence of 2 or 3 tributaries

Received for publication Mar 29, 1991.

From the Department of Surgery (Linford) and Reproduction (McCue, Montavon, Lasley), School of Veterinary Medicine, University of California, Davis, CA 95616.

Supported by the Equine Research Laboratory with funds provided by the Oak Tree Racing Association, the State of California satellite wagering fund, and contributions by private donors.

The authors thank L. Laughlin and M. A. Haggerty for assistance in performing the hormone assays.

[a] PromAce, Aveco Co Inc, Fort Dodge, Iowa.
[b] Rompun, Mobay Corp, Animal Health Division, Shawnee, Kan.
[c] Torbugesic, Fort Dodge Laboratories, Fort Dodge, Iowa.
[d] Abott Laboratories, North Chicago, Ill.
[e] Silastic, Dow Corning Corp, Midland, Mich.
[f] Tygon, Norton Co, Akron, Ohio.

anastomosing to form the ovarian branch of the ovarian vein (Fig 1). Attempts were not made to identify the uterine branch of the ovarian vein and its junction with the ovarian branch of the ovarian vein was rarely observed; thus, it was usually not determined whether the cannula tip lay proximal or distal to the junction of the uterine and ovarian branches of the ovarian vein. When an area of confluence of tributaries of the ovarian vein could not be visually identified, the cannula was advanced 5 to 12 cm proximal from its entry site near the ovary. Digital palpation was used to be certain that the cannula tip remained within the ovarian vein at least 4 to 5 cm distal to the junction of the ovarian vein and caudal vena cava. Periodic aspiration of 3 to 5 ml of venous blood ensured attainment of good retrograde blood flow prior to securing the cannula in place.

Ligatures of 2-0 polydioxanone[g] were placed proximally and distally on the cannulated tributary over the cannula and tightened sufficiently to slightly indent the cannula wall and secure it in place without reducing the cannula lumen size enough to appreciably interfere with flow of blood during aspiration. The cannulated tributary was additionally ligated between the ovary and cannula entry site, using 2-0 polydioxanone. The incision in the broad ligament was closed, using 3-0 polydioxanone. Interrupted sutures of 2-0 polydioxanone were also used to fix the cannula to the broad ligament. The cannula was passed through the abdominal musculature approximately 6 cm cranial to the grid incision. A flexible sterile pipette[h] was used to tunnel the cannula ventrally from where it exited the abdominal musculature through the subcutaneous tissue for approximately 15 cm before being exteriorized through a 1-cm skin incision where stay sutures of 2-0 polydioxanone were used to secure the cannula to the subcutaneous tissues.

[g] Ethicon Inc, Somerville, NJ.

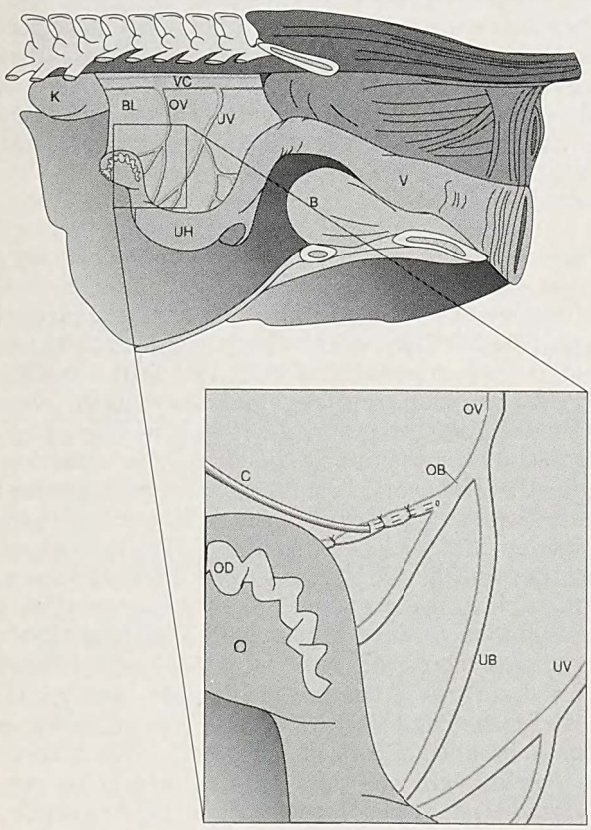

Figure 1—Schematic showing the general location of the reproductive tract in the equine abdomen and an enlargement demonstrating the typical placement location of a cannula. The cannula tip has been positioned at the confluence of 2 tributaries joining to form the ovarian branch of the ovarian vein. The cannulated tributary has been ligated once near the ovary and in 2 places over the cannula, securing it in place. C = cannula; O = ovary; OD = oviduct; OV = ovarian vein; OB = ovarian branch of the ovarian vein; UB = uterine branch of the ovarian vein; UV = uterine vein; VC = vena cava; UH = uterine horn; V = vagina; B = urinary bladder; BL = broad ligament; K = kidney.

Antimicrobial therapy consisted of 7 days of trimethoprim-sulfamethoxizole (5 mg/kg, PO, q 12 h) administration, commencing 2 hours prior to surgery. Patency of each cannula was maintained by manual flushing with 5 ml of heparinized saline solution (33 U/ml) twice daily and 0.05-ml boluses of concentrated heparinized saline solution (150 U/ml) every half hour by use of a programmable peristatic pump.[i] The pump was attached to an elastic wrap[j] placed around the abdomen of the mare. Precautions were taken to keep the cannula exit site cleaned daily with 70% alcohol after surgery.

Sample collection—Paired jugular and ovarian venous blood samples were collected twice daily during the periovulatory period, then once daily until cannulae were no longer patent. Blood samples were centrifuged, and the plasma was frozen (−20 C) until analysis. Ovarian follicular status was monitored daily by transrectal palpation and ultrasonography.

Hormone assays—Concentrations of progesterone, estrone, and estradiol in paired jugular and ovarian venous plasma samples were determined by use of radioimmunoassay after celite column chromatography. Progesterone antisera cross-reacted with 5-β, pregnane-3,20 dione (13%), 5-α, pregnane-3,20 dione (5%) and 17-α, hydroxyprogesterone (2%), but cross-reactivity was < 2% for 15 other steroids tested. Estrone antisera[k] cross-reacted with equilenin (9.2%), equilin (4.6%) and estradiol (1.5%); cross-reactivity with 8 other steroids tested was < 1%. Estradiol antisera had limited cross-reaction with estrone (4%), and cross-reactions with 13 other steroids tested was < 1%. However, most potentially cross-reacting steroids in equine plasma samples were eliminated from measurement by celite column chromatography. Briefly, a 0.5-ml aliquot of jugular vein plasma or 0.2 ml of ovarian vein plasma was combined with 800 to 1,000 counts/min (cpm) each of [^{3}H]progesterone, [^{3}H]estrone and [^{3}H]estradiol (100 to 140 μCi/mg)[l] and extracted with 5 ml of ether. Extracted samples were dried under nitrogen and reconstituted in 0.5 ml of iso-octane. Each reconstituted sample was passed through a celite column containing 0.7 g of a celite:ethylene glycol mixture (2:1, w:v). Progesterone, estrone, and estradiol fractions were subsequently eluted, using 100% iso-octane, 15% ethyl acetate:85% iso-octane, and 40% ethyl acetate:60% iso-octane rinses, respectively. All eluates were dried under nitrogen in a 37 C waterbath and reconstituted in 1 ml of phosphate-buff-

[h] Infusion pipette, Har-Vet, Spring Valley, Wis.
[i] Pulsamat, Ferring Laboratories Inc, Ridgewood, NJ.
[j] Elastikon, Johnson & Johnson, New Brunswick, NJ.
[k] Anti-Estrone-6-thyroglobulin, ICN ImmunoBiologicals, Lisle, Ill.
[l] New England Nuclear, Boston, Mass.

ered saline solution containing 1% gelatin. A 0.3-ml aliquot of each reconstituted sample was counted for steroid recovery, and 0.5 and 0.2 ml of reconstituted samples from jugular venous plasma and ovarian venous plasma, respectively, were assayed for steroid hormone concentrations. The final hormone concentration was determined after correction for methodologic losses during extraction and celite column chromatography after calculating the percentage of recovery of the radioactive tracer. The respective intra- and interassay coefficients of variation were 15.7 and 25% for progesterone; 25 and 16% for estrone; and 11.7 and 22% for estradiol. Sensitivity of the progesterone, estrone, and estradiol assays was < 0.1 ng, 10 pg, and 10 pg/ml, respectively. Differences between ovarian vein and jugular vein hormone concentrations were assessed, using a Student's *t* test for paired samples. All values are given as the mean ± SEM.

Polyvinyl chloride cannulae were removed by application of gentle traction at the point where the cannula exited the skin. A second laparotomy for cannulae removal was, therefore, not required, except to remove the silastic cannula, which became too friable to be removed by traction alone. For 1 year after removal of the cannulae, the reproductive tract of 2 of the 3 mares with PVC ovarian vein cannulae was examined periodically by palpation and ultrasonography. The other mare with a PVC cannula was euthanatized with the cannula in place to verify cannula position and to evaluate the inflammatory response associated with chronic cannulation.

Results

The ovarian venous cannulae (n = 4) remained patent for a mean (± SEM) duration of 36.8 ± 6.2 days. Manipulation of the genital tract and cannula per rectum was periodically required to obtain a blood sample via the silastic cannula. One PVC cannula was still patent 51 days after surgery, when the mare was euthanatized. Postmortem examination revealed adhesions along the cannula between the peritoneum, broad ligament, and ovary. The ligated portion of the cannulated tributary of the ovarian vein contained a thrombus surrounding the cannula between the ligatures. The cannula, however, was patent and its tip lay free within the ovarian vein proximal to the junction of 2 tributaries. Irritation or thrombus formation was not evident within the portion of the ovarian vein containing the cannula tip. The location of the cannula tip in the ovarian vein was 11 cm proximal to the ovary and 6 cm distal to the junction of the ovarian vein and vena cava. A discrete uterine branch of the ovarian vein was not identified.

None of the mares manifested signs of peritonitis, such as fever, inappetence, lethargy, or abdominal discomfort during the time the cannula was in place. One mare was administered trimethoprim-sulfamethoxizole for 10 days because 2 weeks after surgery, it developed signs of localized infection at the site where the cannula exited the skin. Further problems were not observed. Two mares examined 1 year after cannula removal had normal follicular activity on the ovary ipsilateral to the cannula, but the mesovarium was adhered to the body wall in each mare.

Concentrations of progesterone, estrone, and estradiol were measured in 141 paired samples from the jugular and ovarian veins. Mean progesterone concentration during mid-diestrus in the ovarian vein ipsilateral to the corpus luteum (1,663.8 ± 238.8 ng/ml) was significantly ($P < 0.001$) higher than mean concentration measured in paired samples (n = 31) from the jugular vein (6.1 ± 0.3 ng/ml). Mean daily concentration of progesterone in the ovarian vein contralateral to the corpus luteum measured in 1 mare during days 6 to 12 of diestrus (37.3 ± 8.4 ng/ml) was also significantly ($P < 0.01$) higher than mean concentration in paired jugular venous blood samples (10.2 ± 0.8 ng/ml).

The daily progesterone profile during the periovulatory period was well documented by values for serially obtained samples in 1 mare. At the onset of estrus, progesterone concentration in ovarian and jugular venous blood samples decreased to < 0.5 ng/ml, indicating that complete luteolysis may have occured (Fig 2). One day prior to ovulation, progesterone concentration in the ovarian vein was > 1 ng/ml, then increased to > 10 ng/ml on the day of ovulation. Concentration in the jugular vein, however, remained < 0.5 ng/ml until 2 days after ovulation. Five days after ovulation, progesterone concentration was 1,514.86 and 7.65 ng/ml in ovarian and jugular venous blood samples, respectively.

Estrone concentration in jugular venous blood determined after celite column separation was below the limit of sensitivity (10 pg/ml) in 53% of the samples assayed. Concentration of estrone in ovarian venous blood was significantly ($P < 0.001$) higher, ranging from 2,787.3 ± 500.6 pg/ml during diestrus (n = 27) to 3,800.3 ± 1,655.9 pg/ml during estrus (n = 9). Estradiol concentration was near or below the limit of sensitivity of the assay (10 pg/ml) in 74% of the 0.5-ml aliquots of jugular venous blood used in this study. Ovarian venous blood estradiol concentration was significantly ($P < 0.001$) higher, ranging from a mean 1,053.2 ± 303.1 pg/ml during diestrus (n = 31) to 3,353.8 ± 1,052.8 pg/ml during estrus (n = 13).

Paired point-in-time ovarian vein and jugular vein plasma samples were collected at surgery from 1 mare 6 days after ovulation and from 2 mares during estrus. Samples were analyzed to compare with results obtained

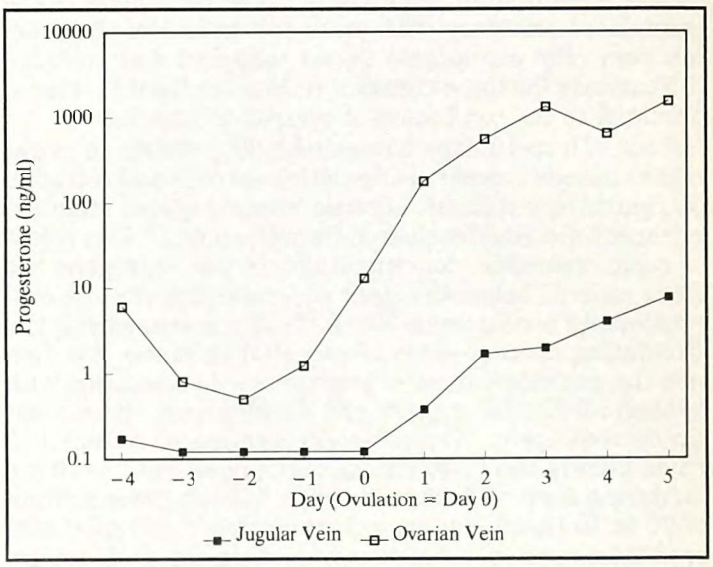

Figure 2—Concentration of progesterone in the ovarian and jugular veins of a mare during the periovulatory period.

from chronic cannulations. During diestrus, concentration of progesterone in the jugular vein (11.2 ng/ml) of the former mare was 308 times less than the concentration in the paired sample collected from the ovarian vein (3,448.4 ng/ml). Estradiol concentration in the jugular vein of the 2 mares tested during estrus was below the limit of detection (10 pg/ml), whereas concentration in the ovarian vein was 500 and 320 pg/ml.

Discussion

To our knowledge, our technique to successfully collect and analyze ovarian venous blood from mares over a prolonged period is unique. Collection of single point-in-time samples from the ovarian vein of mares under general anesthesia has been reported.[7] Ovarian or utero-ovarian venous cannulae have also been used to monitor ovarian steroid hormone production in rats,[3,9,10] sheep,[4,8] pigs,[11] and women[12]; prostaglandin release in cattle[6] and sheep[8,13-15]; inhibin production in sheep[16] and pigs[5]; and oxytocin production in sheep.[17] The number of successful long-term (> 21 days) ovarian vein cannulations described is limited, presumably because of the technical difficulties. One technique in sheep[8] was reported in which silastic cannulae, continuous infusion of heparinized saline solution, and temporary vena cava occlusion were used.

In this study, a silastic cannula was adequate, but had some disadvantages, compared with PVC cannulae that were subsequently used. Flexibility of the silastic tubing allowed the walls to collapse easily during sample aspiration, especially if acute bends existed in the tubing. Manipulation of the genital tract per rectum was, therefore, often needed to successfully obtain a sample. These problems were rarely associated with the PVC cannulae, which were flexible, but resisted collapse. Both types of cannulae were well tolerated by the tissues and vasculature. It is thought that factors other than cannula composition may influence sample collection success, such as vascular thrombosis and location of the cannula tip. For instance, to be most effective, we found it necessary to advance the cannula tip through the cannulated tributary to a point slightly proximal to the confluence of the cannulated tributary with other tributaries of the ovarian vein. The cannulated vessel collapsed and occluded the cannula during aspiration unless the tip was located proximal to the confluence of several tributaries.

Lack of a specific sex hormone-binding protein in mares makes measurements of circulating estrone and estradiol concentrations difficult because nonconjugated steroidal estrogens are rapidly cleared from the blood.[2] As a result of rapid clearance, concentrations of free estrogens are often near or below the limit of sensitivity of most conventionally used assays. The difficulty in measuring low circulating concentration of estradiol in mares has limited the characterization of ovarian events associated with dynamic follicular growth and development throughout the estrous cycle. Whereas concentration of estradiol in blood during the breeding season ranges from < 10 pg/ml during most of the estrous cycle to peak concentration of 20 to 30 pg/ml just prior to ovulation,[18] estradiol concentration in the ovarian vein detected in our study ranged from approximately 1,000 pg/ml during diestrus to > 3,000 pg/ml during estrus. In contrast to the threefold range of concentrations of estradiol in the ovarian vein throughout the estrous cycle, concentration of estrone ranged only 0.5-fold in the same samples.

Progesterone concentration in blood is approximately 2 orders of magnitude greater than the circulating concentration of estradiol and, therefore, is easier to detect, using conventional radioimmunoassays or enzyme immunoassays.[19] The onset, duration, and demise of luteal function in mares, using concentration of progesterone in blood, has been well described.[20] Data from this study extend those observations by indicating that equine ovaries may begin to secrete progesterone into the ovarian vein at least 1 day prior to ovulation. Preovulatory synthesis and secretion of progesterone has been reported in bitches,[21] but has not been reported in horses, to our knowledge. This study also provides endocrine data to support histologic evidence of luteinization of the preovulatory follicle previously reported in mares.[22] Positive gradients of progesterone in the ovarian vein contralateral to the ovary containing the corpus luteum also indicate that progesterone may be synthesized and released in the absence of distinct luteal tissue, as detected by ultrasonography. In our mares, the largest follicle present in the ovary contralateral to the ovary containing the corpus luteum was 24 mm in diameter and ovulations were not detected during daily ultrasonography. These findings indicate that partial luteinization may have occurred during the luteinizing hormone surge.

Progesterone concentration measured in the cannulated ovarian vein of the mares in this study was similar to concentration reported for single samples collected from the ovarian vein of pregnant mares (1,649 ng/ml) prior to formation of secondary corpora lutea[7] and from the utero-ovarian vein of cannulated ewes (220 to 1,846 ng/ml during mid-diestrus),[18] and was greater than the range found in the utero-ovarian vein of pigs on day 14 of pregnancy (30 to 300 ng/ml).[11]

Maintenance of long-term (> 21 days) ovarian vein cannulations has been fraught with difficulties in horses and other species.[8] However, results of this study indicate that patent long-term ovarian vein cannulation can be achieved in mares and that such cannulations can be used to document changes in ovarian steroid secretion. Success of this technique was, in part, attributed to selection of cannula material, selective positioning of the cannula tip, and continuous slow infusion of heparinized saline solution through the cannula to discourage thrombus formation at the cannula tip between sample collection periods. This technique can now be used to monitor ovarian hormone secretion during various stages of the reproductive cycle and to differentiate hormone production from the ovary vs production from the fetal-placental unit during pregnancy. The ability to measure ovarian hormones at the site of secretion should open new avenues of research and provide fundamental information on equine reproductive endocrinology.

References

1. Stabenfeldt GH, Hughes JP, Evans JW. Ovarian activity during the estrous cycle of the mare. *Endocrinology* 1972;90:1379–1384.

2. Hillman RB, Loy RG. Oestrogen excretion in mares in relation to various reproductive states. *J Reprod Fertil* 1975;23(Suppl):223–230.

3. Shaikh AA, Shaikh SA. Adrenal and ovarian steroid secretion in

the rat estrous cycle temporally related to gonadotropins and steroid levels found in peripheral plasma. *Endocrinology* 1975;96:37–44.

4. Thorburn GD, Cox RI, Currie WB, et al. Prostaglandin F and progesterone concentrations in the utero-ovarian venous plasma of the ewe during the oestrous cycle and early pregnancy. *J Reprod Fertil*, 1973;18(Suppl):151–158.

5. Redmer DA, Christenson RK, Ford JJ, et al. Inhibin-like activity in ovarian venous serum after unilateral ovariectomy in prepubertal gilts. *Biol Reprod* 1986;34:357–362.

6. Knickerbocker JJ, Thatcher WW, Foster DB, et al. Uterine prostaglandin and blood flow responses to estradiol-17β in cyclic cattle. *Prostaglandins* 1986;31:757–776.

7. Squires EL, Ginther OJ. Collection technique and progesterone concentration of ovarian and uterine venous blood in mares. *J Anim Sci* 1975;40:275–281.

8. Hooper SB, Walker DW, Thorburn GD. Cannulation of the utero-ovarian vein in intact ewes: hormone concentrations and blood gas levels during the oestrous cycle and early pregnancy. *Acta Endocrinol* 1986;112:253–262.

9. Varga B, Horváth E, Folly G, et al. Study of the luteinizing hormone-induced increase in ovarian blood flow during the estrous cycle in the rat. *Biol Reprod* 1985;32:480–488.

10. Varga B, Horváth E, Zsolnai B. Effects of oxytocin and vasopressin on the ovarian blood flow, progesterone and oestradiol-17β secretion in oestrous rats. *Acta Endocrinol* 1985;110:271–275.

11. Kotwica J, Stefanczyk S, Debek J, et al. The lack of relationship between progesterone level in utero-ovarian vein and the number of corpora lutea in the pigs. *Exp Clin Endocrinol* 1984;84:356–359.

12. Moltz L, Schwartz U, Sörensen R, et al. Ovarian and adrenal vein steroids in patients with nonneoplastic hyperandrogenism: selective catheterization findings. *Fertil Steril* 1984;42:69–75.

13. Ottobre JS, Lewis GS, Thayne WV, et al. Mechanism by which progesterone shortens the estrous cycle of the ewe. *Biol Reprod* 1980;23:1046–1053.

14. Silvia WJ, Ottobre JS, Inskeep EK. Concentrations of prostaglandins E_2, $F_{2\alpha}$ and 6-keto-prostaglandin $F_{1\alpha}$ in the utero-ovarian venous plasma of nonpregnant and early pregnant ewes. *Biol Reprod* 1984;30:936–944.

15. Vincent DL, Inskeep EK. Role of progesterone in regulating uteroovarian venous concentrations of $PGF_{2\alpha}$ and PGE_2 during the estrous cycle and early pregnancy in ewes. *Prostaglandins* 1986;31:715–733.

16. McNeilly AS, Baird DT. Episodic secretion of inhibin into the ovarian vein during the follicular phase of the oestrous cycle in the ewe. *J Endocrinol* 1989;122:287–292.

17. Hooper SE, Watkins WB, Thorburn GD. Oxytocin, oxytocin-associated neurophysin, and prostaglandin $F_{2\alpha}$ concentrations in the utero-ovarian vein of pregnant and nonpregnant sheep. *Endocrinology* 1986;119:2590–2597.

18. Plotka ED, Foley CW, Witherspoon DW, et al. Periovulatory changes in peripheral plasma progesterone and estrogen concentrations in the mare. *Am J Vet Res* 1975;35:1359–1362.

19. Munro C, Stabenfeldt GH. Development of a microtitre plate enzyme immunoassay for the determination of progesterone. *J Endocrinol* 1984;101:41–49.

20. Hughes JP, Stabenfeldt GH, Evans JW. Clinical and endocrine aspects of the estrous cycle of the mare, in *Proceedings*. Am Assoc Equine Pract 1972;18:119–148.

21. Concannon PW, Hansel W, McEntee K. Changes in LH, progesterone and sexual behavior associated with preovulatory luteinization in the bitch. *Biol Reprod* 1977;17:604–613.

22. Kenney RM, Condon W, Ganjam VK, et al. Morphologic and biochemical correlates of equine ovarian follicles as a function of their state of viability or atresia. *J Reprod Fertil* 1979;27(Suppl):163–171.