Pferdeheilkunde – Equine Medicine 40 (2024) 3 (May/June) 204–212

DOI 10.21836/PEM20240301

Correlation between rectal and surface temperature measurements in horses – investigating thermography for infection disease screening protocols

Ralph Lutz[1], Anne Monod[1], Gary Delalay[1], Beat Wampfler[2], Anton Fürst[3] and Stéphane Montavon[1]

[1] Veterinary Department of the Swiss Armed Forces, Bern, Switzerland
[2] National Equestrian Centre (NPZ), Bern, Switzerland
[3] Equine Department, Vetsuisse-Faculty, University of Zurich, Zurich, Switzerland

Summary: Body temperature in the horse is a reference measurement that is considered to be an excellent health indicator. During the COVID-19 pandemic, the use of infrared thermal imaging for fever screening became widespread to detect changes in human body temperature. During the 2021 outbreak of EHV in southern Europe, quarantine and confinement were quickly imposed as the main control measures. This impacted equestrian sport for many months and caused relevant damage. To prevent repetition of these events, the equine sport sector introduced rules to monitor the temperature of the horses before, during and after competitions. The first objective of this study is to assess whether Infrared Thermography (IRT) measurement of either the anus or forehead surface temperature using a FLIR thermal imaging camera is an appropriate alternative to rectal measurements using a thermometer for determining body temperature in horses. The second objective is to assess the possibility of using IRT body temperature measurement on a large scale, for example in the case of an infectious disease epidemic such as EHV-1. 40 healthy geldings from the Swiss Armed Forces with a median age of 7.5 years (range: 4 to 17 years, SD 3.83 years) were used. The study was divided into three periods. The first was the pilot study with 13 horses during the summer. The second was during the winter with 16 horses and the third with 11 horses in early spring. 10 horses in the second study period and 4 horses in the third wore a blanket, while the other 26 horses did not. A conventional veterinary digital thermometer and the FLIR E86 thermal imaging camera were used. The anal IRT measurement was made at a distance of 10 cm centred on the middle of the anus. The forehead measurement was made on the midline between the eyes at distances of 20 and 30 cm. All measurements were taken three times a day (early morning, midday and late afternoon). The same location was used over all three testing periods. The median difference between measurements of rectal temperature and surface anal temperature was 0.9 °C (SD = 0.96 °C – p value: $<2.2 \times 10^{-16}$). There was a variation between summer and winter (p value: $<2.2 \times 10^{-16}$). The ambient temperature was an important parameter influencing the surface anal temperature in our data (p value = 6.34×10^{-29}). The median difference between measurements of rectal temperature and surface forehead temperature was 15.2 °C (SD = 2.83) at 20 cm and 15.3 °C (SD = 2.84 °C) at 30 cm. Repeated measurements of the surface anal temperature with the FLIR showed that the method is reproducible, with only small differences between the measurements. Neither the surface temperature of the anus nor the forehead as measured with the FLIR allowed efficient prediction of equine rectal temperature. The precision of the methodology applied both to the anus and the forehead was too low to allow the effective implementation of this technology to evaluate equine body temperature. In addition, this method is also insufficiently accurate for measuring body temperatures on a large-scale during events with a large number of horses.

Keywords: horse, body temperature, rectal measurement, thermographic measurement, large-scale measurement, forehead, anus

Citation: Lutz R, Monod A, Delalay G, Wampfler B, Fürst A, Montavon S (2024) Correlation between rectal and surface temperature measurements in horses – investigating thermography for infection disease screening protocols. Pferdehlk Equine Med 40, 204–212; DOI 10.21836/PEM20240301

Correspondence: med. vet. Ralph Lutz, Veterinary officer, Veterinary Department of the Swiss Armed Forces, Worblentalstrasse 36, CH-3063 Bern, Switzerland; ralph.lutz@vtg.admin.ch

Submitted: 18. März 2024 | **Accepted:** 21. März 2024

Introduction

Body temperature is a major area of interest within the fields of veterinary medicine and physiology; as a reference measurement it is considered to be an excellent health indicator. The clinical thermometer introduced in the mid-19th century by Wunderlich has been replaced by digital thermometers, radiometric devices and microchip identification technology [1–3]. During the COVID-19 pandemic, the use of infrared thermal imaging for fever screening became widespread to detect changes in human body temperature. Infrared detection for fever screening is currently in use worldwide to control air travel and access to public places [4,5]. Interest for these new techniques also arose in veterinary medicine and they are now being used in the equestrian environment. Infrared thermography (IRT) is a non-contact, non-invasive technique that accurately detects temperature differences on the surface of an object or anatomical structure [6,7]. Abnormal body temperature in animals is a major indicator of disease and IRT can assess changes in body surface temperature quickly and remotely. This technology can potentially be applied to a myriad of diseases of various aetiologies across a wide range of host species in veterinary medicine [8].

Thermography used in the equestrian environment is a valuable tool for detecting the invisible, locating a problem area, its radiation and its intensity. This non-invasive technique consists of photographing and measuring the differences in temperature emitted by the animal's body. These thermal variations are indicators that can help to identify inflamed areas of the body or an area of trauma. Today, thanks to the evolution of technology, the analysis of this data gives the veterinarian, therapist, trainer, farmer, owner, rider or equine professional the means to visualise abnormal temperatures and thus to better understand the source of the problem. This can help to efficiently determine the appropriate treatment [9–18]. IRT is also a preferred technique for monitoring recovery in horses, in order to check – and adapt if necessary – ongoing treatment to ensure optimum effectiveness [19]. In addition, thermography does not emit any radiation. It is therefore safe for both the horse and personnel.

Equid herpesvirus type 1 (EHV-1) is a worldwide cause of respiratory disease in horses. The infection is also associated with complications, including abortion and Equid herpesvirus-associated myeloencephalopathy (EHM). EHV-1 is a highly contagious disease that spreads horizontally via direct nose-to-nose contact or indirectly via airborne transmission or fomites [20–23]. Typically, only the viraemic phase in the adult horse is accompanied by fever (>38.4 °C) [24]. In stables with clinical cases of fever and/or EHM, seroconversion was detected in up to 90% of all horses, including horses without clinical signs [25,26]. When appropriate measures are taken, outbreaks can be successfully contained to a single stable unit [27].

During the outbreak of EHV in southern Europe in 2021, quarantine and confinement were quickly imposed as the main control measures. This impacted all equestrian sports for many months and caused relevant damage. To attempt to prevent this from occurring again, the equine sport sector introduced rules to monitor the serological status and the temperature of the horses before, during and after competitions [28].

In the FEI (Fédération Equestre Internationale) disciplines, checks on horses arriving at an international event have become very important and compulsory. As well as checking the identity and vaccination status of the horses, this also includes checking the rectal temperature when horses are unloaded from their transport. Horses with a temperature above 38.5 °C are immediately placed in quarantine stables and will subsequently be examined for their EHV status. The FEI has also developed a smartphone application (FEI Horse App) and it is required that the rectal temperature of all competing horses must be uploaded onto it twice a day for the three days prior to the arrival at the international stables. However, rectal temperature measurements prior to and on arrival take time and must be carried out meticulously, which has sparked massive interest for precise, non-invasive alternate methods to measure equine body temperature.

Clearly, other equine infectious diseases cause fever, but it was the outbreak of EHV-1 that triggered the implementation of large-scale body temperature measurements.

As an outbreak of Equine Herpes Virus 1,4 occurred at major show jumping competitions, mainly in Valencia (Spain) in March 2021, many other major FEI events were threatened or even cancelled. The equestrian world was under pressure and had to show resilience and patience. The FEI also had to react and set up a monitoring system, particularly for equine body temperature. The Swiss Armed Forces have a large number of horses, particularly at their centre in Berne (in two locations), and therefore quickly put a protection concept in place.

As studies have already been carried out to evaluate the usability of IRT as an indicator for exertional heat illness (EHI) in racehorses or at endurance competitions [29–31], the first objective of this study was to assess whether thermographic measurement of anus or forehead surface temperature using a FLIR thermal imaging camera is an appropriate alternative to rectal measurements using a thermometer for determining body temperature in horses. Therefore, the reproducibility and accuracy of the FLIR methodology was evaluated and compared to rectal measurement. The second objective was to determine the possibility of using body temperature measurement by IRT on a large scale, in the case of an EHV-1 epidemic, for example.

Materials and methods

Animals

The study population consisted of 40 healthy geldings from the Swiss Armed Forces with a median age of 7.5 years (range: 4 to 17 years, SD 3.83 years). The study was divided into three periods. The first was the pilot study with 13 horses during the summer from 2022-07-25 to 2022-08-18. The second was during the winter with 16 horses from 2023-01-30 to 2023-02-23 and the third was with 11 horses during the early spring from 2023-03-08 to 2023-03-30. 10 horses in the second study period and 4 horses in the third wore a blanket, while the other 26 horses did not.

Preparation for measurements

Measurements were taken at the same grooming area in the same stable for all three study periods. The first step was to prepare the materials that were stored in a wall cupboard in the stable during each study period. This consisted of a veterinary rectal thermometer Digi-Vet SC12 (Kruuse, Denmark), a weather station IROX METE-ON89 (Germany) with digital display of the ambient temperature including humidity and a printed blank list of all horses to be sampled. The FLIR E86 thermal imaging camera was taken from the office to the stable each time. The weather station was also always placed in the same location in the open wall cupboard of this stable.

Depending on the availability of the stable staff, someone would bring the horse from its stall to the grooming area. During the pilot study, three people carried out the measurements with the thermal imaging camera. For the second and third study periods, the measurements were taken by a different person each time but this person was present for the entire testing period and the thermal imaging camera measurements were carried

out by one person on each testing day. Once the horse was tied up, the rectal thermometer was inserted into the anus until it reached the display. Care was taken to ensure that the sensor of the device was pressed against the intestinal wall in order to measure the actual temperature of the intestinal wall and not that of any faeces present. When the rectal thermometer signal was heard, it was removed from the anus and the reading was read and recorded. If the horse was wearing a blanket, only the caudal part of the blanket was removed to ensure good access to the anus. At the end, the horse was returned to its stall and the procedure was repeated with the next horse.

Experimental Design and Device

The body temperature of the horses included in the study was measured three times a day, at 7am, 1pm and 7pm. For each point in time, the temperature was measured once with a rectal thermometer and several times using a thermal imaging camera FLIR E86 (Teledyne FLIR LLC) paired with a FLIR Flex View™ dual field-of-view lens (Fig. 1).

Fig. 1 The FLIR E86 Advanced Thermal Imaging Camera. (Credit: Teledyne FLIR LLC). | *Die leistungsstarke Wärmebildkamera FLIR E86. (Bild Teledyne FLIR LLC).*

During the pilot study, the thermal imaging camera was used to take two temperature measurements of the anus from a distance of 10 cm. For the second and third study periods, temperature was also retrieved from the forehead, once with a distance of 20 cm and once with a distance of 30 cm.

Before using the thermal imaging camera, the current ambient temperature and humidity were read from a digital temperature display and if necessary, entered into the thermal imaging camera. This was repeated before taking measurements for each horse. The camera screen was adjusted so that the thermal imaging function was only available in the centre of the live image view. The reason for this setting was that with the pure thermal image view it was difficult to find the exact measuring point depending on the horse. With the help of this setting, the anus could be searched for with the normal camera function and the thermal image function could be directed exactly to the region of the sphincter above the anus at an orientation of 12 o'clock. The thermal imaging camera was placed at a distance of 10 cm to the anus for the measurement, which was controlled by the use of a retractable tape measuring device. For measurement of the forehead temperature, the camera was placed at a distance of 20 and then 30 cm, at the level of the central midline between the eyes.

In practice and for both measurement sites, a slight movement (a few millimetres) of the camera could generate significant temperature differences (up to one degree Celsius).

For the measurement, the tail was held to the side by an assistant so that the measurement could be carried out unhindered by the examiner. After a waiting period of two to three seconds to allow the camera to display a stable value, the measurement was recorded. Between the measuring of two values, the camera was moved sideways away from the horse so that it was pointed at the floor or a stall wall (Fig. 2, 3, 4)

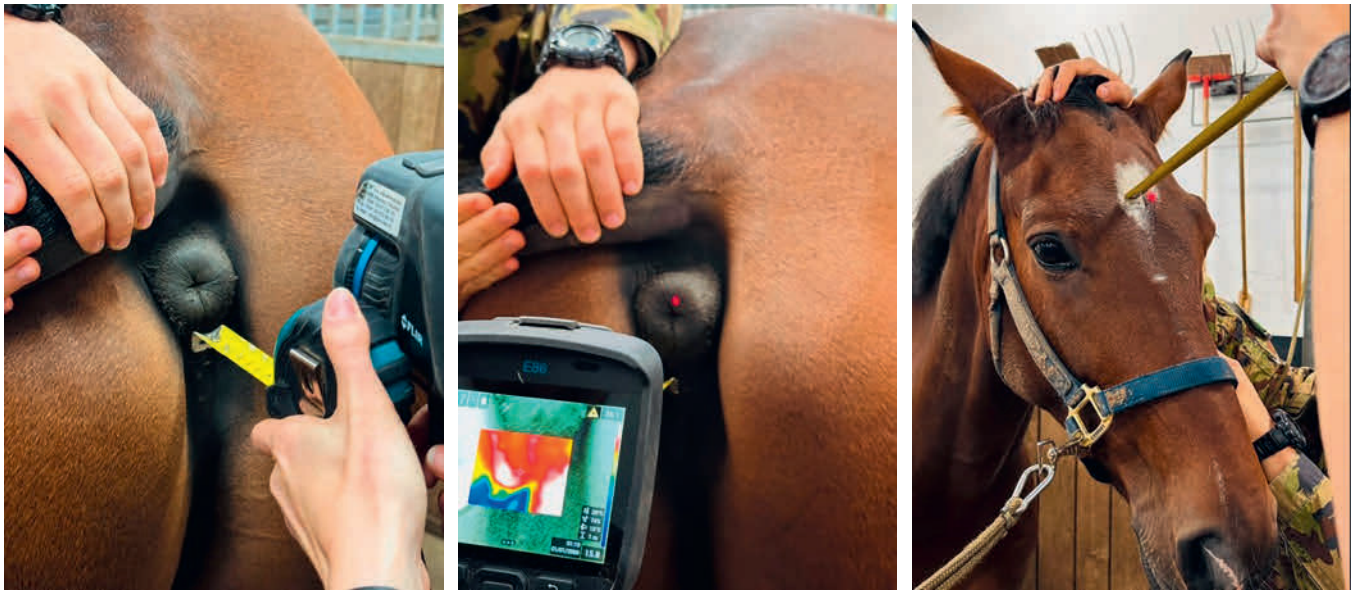

Fig. 2, 3 and 4 The measurement made with the laser point (red) for the anus and forehead - (Credit: Swiss Armed Forces). | *Die Messung mittels Laserpunkt (rot) an After und Stirn. (Bild: Schweizer Armee).*

Statistical analysis

The data were collected in a Microsoft Excel 2021 table (Microsoft Excel, https://www.microsoft.com/en-gb/, RRID:SCR_016137) and loaded in a R Notebook with RStudio 2023.06.1+524 (https://www.rstudio.com/, RRID:SCR_000432) and R 4.3.1 "Beagle Scouts" (R Project for Statistical Computing, https://www.r-project.org/, RRID:SCR_001905) with package readxl 1.4.3 (https://cran.r-project.org/web/packages/readxl/index.html, RRID:SCR_018083). Analyses were performed with packages dplyr 1.1.2 (https://cran.r-project.org/web/packages/dplyr/index.html, RRID:SCR_016708) and tidyr 1.3.0 (https://cran.r-project.org/web/packages/tidyr/index.html, RRID:SCR_017102). Figures were computed in R with packages ggplot2 3.4.2 (https://cran.r-project.org/web/packages/ggplot2/index.html, RRID:SCR_014601).

Results

Surface anal temperature

The median difference between repeated measurements of the surface anal temperature was equal to 0.1 °C (95th percentile = 0.6 °C) (Figure 5).

The median difference between measurements of rectal temperature and surface anal temperature was 0.9 °C (5th percentile = -0.5 °C, 95th percentile = 2.7 °C, SD = 0.96 °C). But even if we add the value of this median difference of 0.9 °C as a correcting summand to the measured surface temperature, we observe that more than half the measured values still vary from the rectal temperature by 0.5 °C or more (Figure 7). The Pearson correlation coefficient between the rectal temperature and surface anal temperature was equal to 0.35 (p value: $<2.2\times$) (Figure 6).

When considering the first sampling period (2022-07-25 to 2022-08-18) as summer and the second and third sampling periods (2023-01-30 to 2023-03-30) as winter, we could find that the difference between the rectal temperature and the adjusted anal surface temperature in our data varied by season, with a generally lower difference in summer than winter (p value $< 2.2\times10^{-16}$) (Figure 7. The ambient temperature was an important parameter influencing the surface anal temperature in our data (p value $= 6.34\times10^{-29}$) according to a generalised linear model that used the rectal temperature and ambient temperature to predict the surface anal temperature.

Forehead surface temperature

The FLIR was also used to record the forehead surface temperature from a distance of 20 cm and 30 cm during the

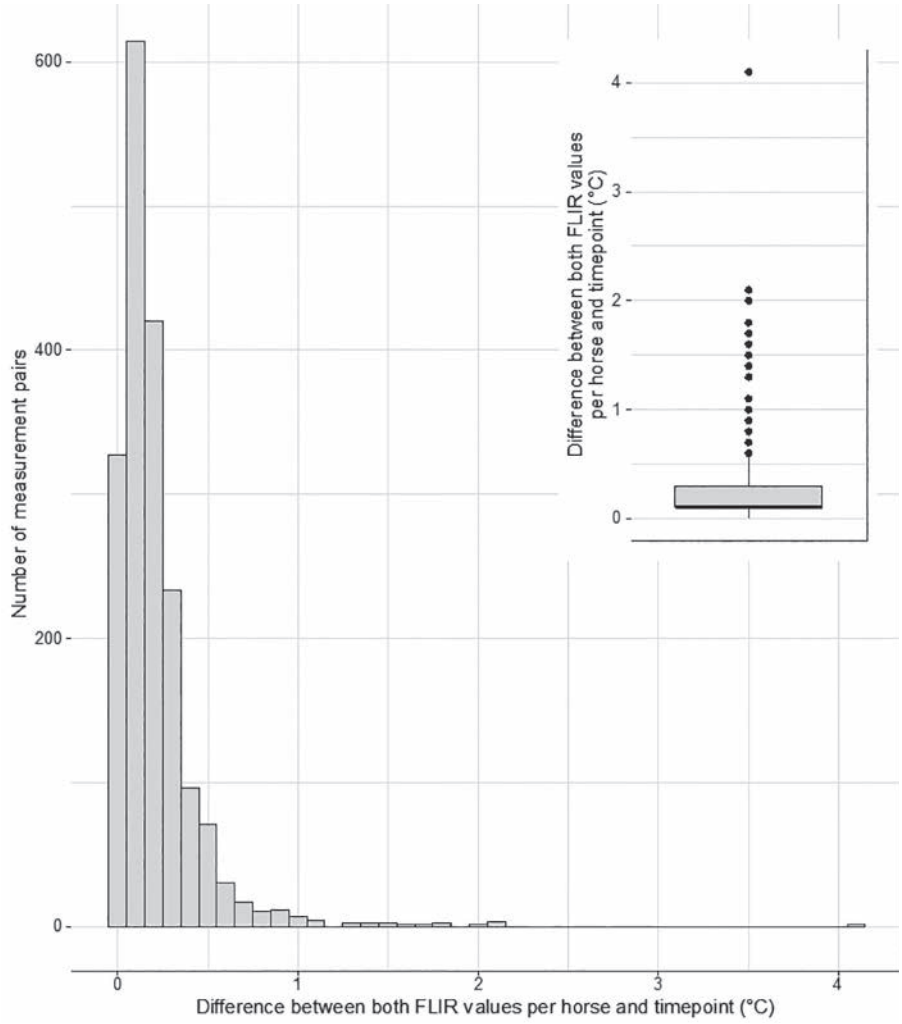

Fig. 5 Difference between two FLIR-measurements of the surface anal temperature taken from the same horse at the same timepoints. | *Differenz zwischen zwei FLIR-Messungen der Analoberflächentemperatur, die von demselben Pferd zu denselben Zeitpunkten vorgenommen wurden.*

measurements for the groups "February 2023" and "March 2023." As only one measurement from each distance was taken for each horse at each time point, the reproducibility of these measurements cannot be assessed.

The median difference between the rectal temperature and surface forehead temperature measurements was 15.2 °C (5th percentile = 10.3 °C, 95th percentile = 19.7 °C, SD = 2.83 °C) when measured from a distance of 20 cm and 15.3 °C (5th

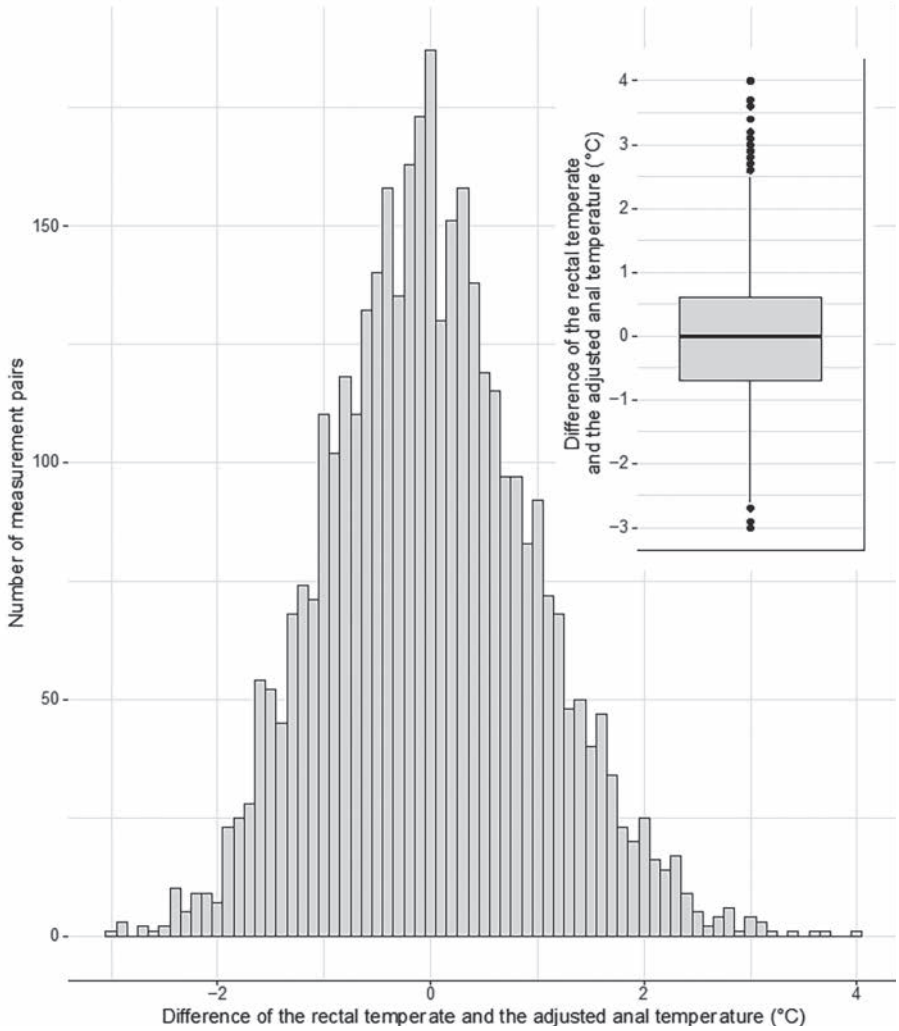

Fig. 6 Difference between the rectal temperature measured with a thermometer and the adjusted surface anal temperature taken with the FLIR, measured on the same horse at the same timepoint. | *Differenz zwischen der mit einem Thermometer gemessenen Rektaltemperatur und der mit dem FLIR gemessenen angepassten Oberflächen-Analtemperatur, gemessen am selben Pferd zum selben Zeitpunkt.*

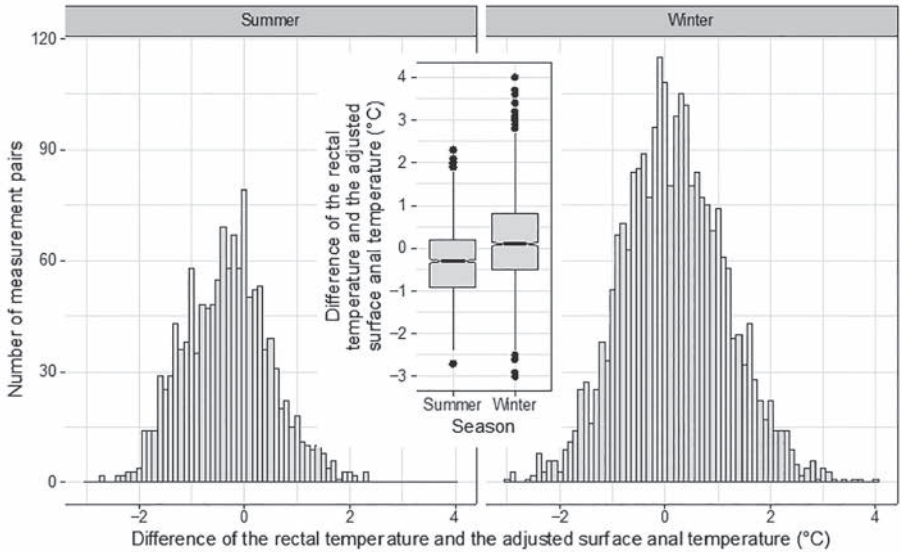

Fig. 7 Difference between the rectal temperature and adjusted surface anal temperature by season. | *Differenz zwischen der rektalen Temperatur und der angepassten analen Oberflächentemperatur nach Jahreszeit.*

percentile = 13.2 °C, 95th percentile = 19.7 °C, SD = 2.84 °C) when it was measured from a distance of 30 cm. After adjusting the forehead surface temperature by adding the median difference from the rectal temperature (i.e. +15.2 °C and +15.3 °C, respectively), we observe that 84 % or more of the adjusted measurements still vary from the rectal temperature by 0.5 °C or more, when measured at a distance of 20 and 30 cm, respectively (Figure 8).

Discussion

Repeated measurements of the surface anal temperature with the FLIR showed that the method is reproducible, with only small differences between the measurements. However, these repeated measurements were done by the same person, with the same FLIR thermal imaging camera and at the same location, permitting no conclusion as to the robustness of the method in terms of the influence of external factors such as personnel, material or stabling conditions. The accuracy of the surface anal temperature measured with the FLIR to predict the rectal temperature measured with a thermometer was not exact, with a median difference of 0.9 °C. We used arithmetic to adjust the FLIR measurements and account for the lack of accuracy. However, the precision of the FLIR methodology is lacking, with more than half of the adjusted FLIR measurements deviating by more than 0.5 °C from the rectal temperature.

This lack in precision could be explained by several factors, including variations in horses, personnel, stabling or meteorological conditions. We noticed in particular that in younger horses (<10 years), the shape of the anus is generally round and regular. Above this age, the shape can vary and become triangular. This complicates the targeting of the centre of the anus and therefore impairs the precision of the measurements. Furthermore, there were significant differences according to seasonality and ambient temperature, implying that the environment is an important factor affecting the precision of the FLIR methodology.

Forehead temperatures were measured for comparison with rectal temperatures. The aim was to test the feasibility of the method rather than its reproducibility.

The surface temperature of the forehead measured with the FLIR did not allow efficient prediction of the rectal temperature of the horses. Even after adjustment for the median difference, more than 80 % of the values deviated by more than 0.5 °C from the rectal temperature. Therefore, this method is a poor predictor of rectal temperature and cannot be used for this purpose.

General comments and alternative methods

Thermographic measurement with the aid of a FLIR thermal imaging camera is not an appropriate method to predict a horse's body temperature in a non-invasive way due to lack of precision. In humans and during the COVID-19 pandemic, the use of thermal imaging to detect persons with elevated body temperature showed very promising results. Remote thermographic measurement of body temperature taking into account the appropriate values of coefficients and algorithms has been a useful criterion for assessing core body temperature. Thermal imaging has been used as a screening procedure of potentially virus-infected people who want to enter public institutions such as airports worldwide [5]. However, this method seems difficult to apply to horses. One of the reasons is practicality; it is difficult to use thermal imaging to measure the frontal temperature of horses while their heads are moving. Moreover, this was not considered in the context of this study. In the context of large-scale measurements of the horse's body temperature, as is the case, for example, when horses arrive at an FEI event or at a stable of the Swiss Armed Forces, the IRT measurement method is not precise enough. In addition, there are many factors that play a major role in the values measured. As a result, this method of measurement, which is insufficiently



Fig. 8 Boxplots of the difference between the rectal temperature and adjusted forehead temperature, measured at a distance of 20 or 30 cm. | *Boxplots der Differenz zwischen der rektalen Temperatur und der angepassten Stirntemperatur, gemessen in einem Abstand von 20 oder 30 cm.*

accurate (>0.5 °C), would not allow horses arriving with a temperature above 38.5 °C to be correctly and reliably identified. As a reminder, according to current FEI regulations, a horse with a temperature above 38.5 °C and its travelling companions must be quarantined.

An alternative method is the implanted bio-microchip. After implementation, it allows for non-invasive measurements of the body temperature, but the implementation process itself is a very invasive procedure. However, it seems to have gained credibility with ethical and animal protection associations. Some authors found that the percutaneous thermal sensing microchip (PTSM) had good potential to act as an alternative option to continuously monitor the body temperature of horses at rest and post-exercise [32] or in foals during the summer in subtropical regions [3]. Additional investigations using the same technique in horses is necessary to adapt this technology broadly to screen the body temperature of horses at racetracks and other equestrian disciplines.

Conclusion

The objective of this study was to determine whether a measurement of the surface temperature of the anus or forehead captured by a thermal imaging camera from a distance of 10 cm (anus) and 20 or 30 cm (forehead), respectively, would be a suitable non-invasive alternative to conventional rectal body temperature measurement. Though the FLIR methodology was reproducible in measuring anal surface temperature, the precision of the methodology applied both to the anus and the forehead was too low to allow the effective implementation of this technology to evaluate the body temperature of horses. In addition, a procedure for measuring body temperatures on a large-scale during events or when horses are call up military service with a large number of horses is also insufficiently accurate. Therefore, thermography is not suitable for infection disease screening protocols.

Conflict of interest statement

The authors have no conflict of interest to declare.

Animal welfare statement

The entire study was carried out after the outbreak of EHV1,4 in southern Spain in March 2021. As the situation remained critical, the horse stables of the Swiss Armed Forces set up a temperature measurement protocol to protect their own horses. All the data used for this study was collected during the years 2022 and 2023. It fully complies with the Swiss legislation concerning the codes of ethical behaviour and animal protection.

Statement of informed consent

All horses belonged to the Swiss Armed Forces. They are aware and consented to inclusion of all gathered data in a scientific publication.

Acknowledgements

The authors would like to thank Dr. med. vet. Lindsay Geitzenauer, DVM, for proofreading and editing the text.

References

1 Ring EF, McEvoy H, Jung A, Zuber J, Machin G (2010) New standards for devices used for the measurement of human body temperature. J Med Eng Technol 34, 249–253 https://doi.org/10.3109/03091901003663836
2 Auclair-Ronzaud J, Benoist S, Dubois C, Frejaville M, Jousset T, Jaffrézic F, Wimel L, Chavatte-Palmer P (2020) No-Contact Microchip Monitoring of Body Temperature in Yearling Horses. Journal of Equine Veterinary Science 86: 102892; https://doi.org/10.1016/j.jevs.2019.102892
3 Kang H, Sole-Guitart A, Mellor VA, Gaughan JB, Zsoldos RR (2022) The use of percutaneous thermal sensing microchips for non-invasive measurement of body temperature in foals during summer seasons in a subtropical region. Animal.16: 100620; https://doi.org/10.1016/j.animal.2022.100620
4 Brioschi ML, Dalmaso Neto C, Toledo Md, Neves EB, Vargas JVC, Teixeira MJ (2023) Infrared image method for possible COVID-19 detection through febrile and subfebrile people screening. Journal of Thermal Biology 112: 103444; https://doi.org/10.1016/j.jtherbio.2022.103444
5 Gorczewska I, Szurko A, Kiełboń A, Stanek A, Cholewka A (2022) Determination of Internal Temperature by Measuring the Temperature of the Body Surface Due to Environmental Physical Factors-First Study of Fever Screening in the COVID Pandemic. Int J Environ Res Public Health19; https://doi.org/10.3390/ijerph192416511
6 Mac Cafferty DJ (2007) The value of infrared thermography for research on mammals. Mammal Review 37, 207–223; https://doi.org/10.1111/j.1365–2907.2007.00111.x
7 Röhlinger P, Günther M, Danz J, Lyhs L, Zimmerhackel M (1979) Zur Anwendung der Infrarottechnik in der Veterinärmedizin. Arch Exp Veterinarmed 33,851–856; PMID: 399434
8 Rekant SI, Lyons MA, Pacheco JM, Arzt J, Rodriguez LL (2016) Veterinary applications of infrared thermography. Am J Vet Res 77, 98–107; https://doi.org/10.2460/ajvr.77.1.98
9 Yarnell KJ, Stratton TD (2014), Brassington R. Monitoring changes in skin temperature associated with exercise in horses on a water treadmill by use of infrared thermography. J Therm Biol 45, 110–116; https://doi.org/10.1016/j.jtherbio.2014.08.003
10 Westermann SWV, Schramel JP, Peham C (2014) Effect of a bandage or tendon boot on skin temperature of the metacarpus at rest and after exercise in horses. Am J Vet Res 75, 375–379; https://doi.org/10.2460/ajvr.75.4.375
11 Westermann S, Buchner HH, Schramel JP, Tichy A, Stanek C (2013) Effects of infrared camera angle and distance on measurement and reproducibility of thermographically determined temperatures of the distolateral aspects of the forelimbs in horses. J Am Vet Med Assoc 242, 388–395; https://doi.org/10.2460/javma.242.3.388
12 Westermann S, Stanek C, Schramel JP, Ion A, Buchner HH (2013) The effect of airflow on thermographically determined temperature of the distal forelimb of the horse. Equine Vet J 45, 637–641; https://doi.org/10.1111/evj.12019
13 Bowers S, Gandy S, Anderson B, Ryan P, Willard S (2009) Assessment of pregnancy in the late-gestation mare using digital infrared thermography. Theriogenology 72, 372–377; https://doi.org/10.1016/j.theriogenology.2009.03.005
14 Levet T, Martens A, Devisscher L, Duchateau L, Bogaert L, Vlaminck L (2009) Distal limb cast sores in horses: risk factors and early detection using thermography. Equine Vet J 41, 18–23; https://doi.org/10.2746/042516408x343046

15 Verna M, Turner TA, Anderson KL (2005) Scintigraphic, radiographic, and thermographic appearance of the metacarpal and metatarsal regions of adult healthy horses treated with nonfocused extracorporeal shock wave therapy – a pilot study. Vet Ther 6, 268–276; PMID: 16299673
16 Ringer SK, Lischer CJ, Ueltschi G (2005) Assessment of scintigraphic and thermographic changes after focused extracorporeal shock wave therapy on the origin of the suspensory ligament and the fourth metatarsal bone in horses without lameness. Am J Vet Res 66, 1836–1842; https://doi.org/10.2460/ajvr.2005.66.1836
17 Tunley BV, Henson FM (2004) Reliability and repeatability of thermographic examination and the normal thermographic image of the thoracolumbar region in the horse. Equine Vet J 36, 306–312; https://doi.org/10.2746/0425164044890652
18 Webbon P (2002) Prohibited practices in equine sport - how to root out malpractice. Veterinary journal (London, England: 1997) 164, 83–84; PMID: 12359459
19 Adair S, Phillips D (2017) Equine Rehabilitation Physical Rehabilitation for Veterinary Technicians and Nurses, 347–376; https://doi.org/10.1002/9781119389668.ch22
20 Oladunni FS, Horohov DW, Chambers TM (2019) EHV-1: A Constant Threat to the Horse Industry. Front Microbiol 10:2668; https://doi.org/10.3389/fmicb.2019.02668
21 Wilsterman S, Soboll-Hussey G, Lunn DP, Ashton LV, Callan RJ, Hussey SB, Rao S, Goehring LS (2011) Equine herpesvirus-1 infected peripheral blood mononuclear cell subpopulations during viremia. Vet Microbiol 149, 40–47; https://doi.org/10.1016/j.vetmic.2010.10.004
22 Edington N, Welch HM, Griffiths L (1994) The prevalence of latent Equid herpesviruses in the tissues of 40 abattoir horses. Equine Vet J 26, 140–142; https://doi.org/10.1111/j.2042–3306.1994.tb04353.x
23 Allen GP (2006) Antemortem detection of latent infection with neuropathogenic strains of equine herpesvirus-1 in horses. Am J Vet Res 67, 1401–1405; https://doi.org/10.2460/ajvr.67.8.1401
24 Maxwell LK, Bentz BG, Bourne DW, Erkert RS (2008) Pharmacokinetics of valacyclovir in the adult horse. J Vet Pharmacol Ther 31, 312–320; https://doi.org/10.1111/j.1365–2885.2008.00957.x
25 van Maanen C, Sloet van Oldruitenborgh-Oosterbaan MM, Damen EA, Derksen AG (2001) Neurological disease associated with EHV-1-infection in a riding school: clinical and virological characteristics. Equine Vet J 33, 191–196; https://doi.org/10.1111/j.2042–3306.2001.tb00600.x
26 Pusterla N, Mapes S, Wilson WD (2008) Diagnostic sensitivity of nasopharyngeal and nasal swabs for the molecular detection of EHV-1. Vet Rec 162, 520–521; https://doi.org/10.1136/vr.162.16.520
27 Goehring L (2008) LP Equine Herpes Myeloencephaloptahy. Current Therapy in Equine Medicine 6; Elsevier, 177–179
28 EHV 1 Report (2023); https://inside.fei.org/system/files/EHV-1_Report_Part_3_FINAL.pdf
29 Brownlow M, Smith T (2021) The use of the hand-held infrared thermometer as an early detection tool for exertional heat illness in Thoroughbred racehorses: A study at racetracks in eastern Australia. Equine Veterinary Education 33, 296–305; https://doi.org/10.1111/eve.13299
30 Barnes A, Kingston J, Beetson S, Kuiper C (2010) Endurance veterinarians detect physiologically compromised horses in a 160 km ride. Equine Vet J Suppl 38, 6–11; https://doi.org/10.1111/j.2042–3306.2010.00225.x
31 Soroko M, Howell K, Dudek K, Wilk I, Zastrzeżyńska M, Janczarek I (2018) A Pilot Study Into the Utility of Dynamic Infrared Thermography for Measuring Body Surface Temperature Changes During Treadmill Exercise in Horses. Journal of Equine Veterinary Science 62, 44–46; https://doi.org/10.1016/j.jevs.2017.12.010
32 Kang H, Zsoldos RR, Skinner JE, Gaughan JB, Mellor VA, Sole-Guitart A (2022) The Use of Percutaneous Thermal Sensing Microchips to Measure Body Temperature in Horses during and after Exercise Using Three Different Cool-Down Methods. Animals (Basel) 12; https://doi.org/10.3390/ani12101267